



Contents lists available at ScienceDirect

Schizophrenia Research

journal homepage: www.elsevier.com/locate/schres

Altered gyrification in schizophrenia and its relation to other morphometric markers

Robert Spalthoff^a, Christian Gaser^{a,b}, Igor Nenadić^{a,c,*}

^a Department of Psychiatry and Psychotherapy, Jena University Hospital, Jena, Germany

^b Department of Neurology, Jena University Hospital, Jena, Germany

^c Department of Psychiatry and Psychotherapy, Phillips University Marburg/Marburg University Hospital UKGM, Marburg, Germany

ARTICLE INFO

Article history:

Received 1 December 2017

Received in revised form 10 June 2018

Accepted 3 July 2018

Available online xxxxx

Keywords:

Schizophrenia

Voxel-based morphometry

Gyrification

Cortical thickness

ABSTRACT

Schizophrenia is modelled as a neurodevelopmental disease with high heritability. However, established markers like cortical thickness and grey matter volume are heavily influenced by post-onset changes and thus provide limited possibility of accessing early pathologies. Gyrification on the other side is assumed to be more specifically determined by genetic and early developmental factors. Here, we compare T1 weighted 3 Tesla MRI scans of 51 schizophrenia patients and 102 healthy controls (matched for age and gender) using a unified processing pipeline with the CAT12 toolbox. Our study provides a direct comparison between 3D gyrification, cortical thickness, and grey matter volume. We demonstrate that significant ($p < 0.05$, FWE corrected) results only partially overlap between modalities. Gyrification is altered in bilateral insula, temporal pole and left orbitofrontal cortex, while cortical thickness is additionally reduced in the prefrontal cortex, precuneus, and occipital cortex. Grey matter volume (VBM) was reduced in bilateral medial temporal lobes including the amygdala as well as medial and dorso-lateral prefrontal cortices and cerebellum. Our results lend further support for altered gyrification as a marker of early neurodevelopmental disturbance in schizophrenia and show its relation to other morphological markers.

© 2018 Elsevier B.V. All rights reserved.

1. Introduction

Schizophrenia is a severe, complex disorder that, in large parts, can be attributed to disrupted neurodevelopment (de Haan and Bakker 2004; Rapoport et al. 2012). These early alterations might arise from both genetic and/or early environmental factors and are thought to result in the complex pattern of symptoms and cognitive deficits manifesting with disease onset.

Brain structural changes in schizophrenia have been shown in a large number of imaging studies, focusing on the anatomical distribution pattern, which includes prefrontal, insular and temporal cortices (Chan et al. 2011; Gupta et al. 2015). Most of these studies have used voxel-based morphometry (VBM) analysis of brain structure, which focuses on volume/density differences, and is susceptible to effects of disease stage/chronicity of illness (Chan et al. 2011; Shah et al. 2016) and antipsychotic treatment (Torres et al. 2013). Similarly, cortical thickness, a surface-based measure, has been shown to be reduced in schizophrenia in prefrontal and temporal cortical areas (Besteher et al. 2016; Goldman et al. 2009; Kubota et al. 2011; Nesvag et al. 2008), yet effects

are also modulated by illness duration and antipsychotic treatment (van Haren et al. 2011).

Gyrification analysis offers a novel approach to analysing brain structure in schizophrenia, since it targets morphometric properties, which are not captured by VBM or cortical thickness analyses. The development of this technique is based on the gyrification index (GI). Initially developed in 2D post-mortem data, the GI describes the ratio of inner vs. outer cortical contours (Armstrong et al. 1995; Zilles et al. 1988). GI shows rapid increase during early stages of brain development and a subsequent plateau after childhood (Zilles et al. 1988; Zilles et al. 2013). Hence, altered gyrification index in adults points to early developmental alterations.

Genetic factors substantially influence the process of cortical folding and formation of gyri and sulci during early brain development in utero and the first years of life (Docherty et al. 2015; Rakic 2009; Zilles et al. 2013), but early environmental effects might add to alterations of gyrification (Haukvik et al. 2012).

Following the initial demonstration of altered GI in schizophrenia (McIntosh et al. 2009; Vogeley et al. 2000), surface-based morphometric methods have been developed to study regional gyrification from MRIs scans in 3D (Luders et al. 2006; Schaer et al. 2008). Subsequently, studies in schizophrenia have shown changes of gyrification (both increases and decreases relative to healthy controls) in prefrontal, insular, and temporal cortices as well as occipital areas (Mancini-Marie et al.

* Corresponding author at: Department of Psychiatry and Psychotherapy, Phillips University Marburg/Marburg University Hospital UKGM, Rudolf-Bultmann-Str. 8, 35039 Marburg, Germany.

E-mail address: nenadic@staff.uni-marburg.de (I. Nenadić).

2015; Nanda et al. 2014; Nenadic et al. 2015a; Nesvag et al. 2014; Palaniyappan and Liddle 2012; Zuliani et al., 2018). These abnormalities might relate to outcome patterns (Palaniyappan et al. 2016) as well as polygenic risk for schizophrenia in healthy subjects (Liu et al. 2017). While heterogeneity across patient studies might be attributable to different methodologies for measuring gyrification, they overall indicate both the genetic impact on gyrification as well as a relation to clinical parameters.

In the present study, we used a surface-based morphometric analysis of gyrification based on the absolute mean curvature approach (Luders et al. 2006) to test the hypotheses that schizophrenia is associated with prefrontal and temporal changes in gyrification, and that these changes only partially overlap with the more commonly used morphometric parameters analysed with VBM or cortical thickness analysis, thus reflecting different aspects of brain morphology.

2. Methods

2.1. Subjects

We included in this study 51 schizophrenia patients (Sz) and 102 age- and sex-matched healthy controls (HC). All subjects provided written informed consent to a study protocol approved by the local Ethics Committee of the Friedrich Schiller University Medical School and in concordance with the Declaration of Helsinki of 1975, as revised in 2008.

Demographic and clinical data are summarized in Table 1. Subjects did not differ in their distribution of gender (SZ: 17 females, 34 males; HC: 33 females, 69 males; Chi-square test: 0.015, $p = 0.903$) or age (HC mean: 33.15 yrs., SD \pm 9.6 yrs.; CI 95%: 31.27–35.03; SZ mean: 35.18 yrs., SD \pm 10.88 yrs.; CI 95%: 32.13–38.24; ANOVA $F = 1.405$, $p = 0.238$). Also, samples did not differ significantly in handedness (using the Edinburgh Handedness Inventory (Edlin et al. 2015; Oldfield 1971), laterality quotient for Sz: mean: 58.80 (CI 95%: 44.27–73.32), HC mean: 69.99 (CI 95%: 63.05–76.94), ANOVA, $F = 2.477$ $p = 0.118$), or in estimated IQ (mean SZ = 105.29 (CI 95%: 101.38–109.21), mean HC = 106.57 (CI 95%: 104.30–108.84), ANOVA, $F = 0.360$, $p = 0.550$). Smaller parts of the sample have been used previously for previous morphometric analyses with other approaches (Nenadic et al. 2015a; Nenadic et al. 2015b).

A board-certified psychiatrist diagnosed Schizophrenia in accordance with DSM IV criteria. Post-hoc evaluation of records also confirmed that patients met DSM-5 diagnosis of schizophrenia.

In patients, the average duration of illness was 8.8 years with an average age of onset of 25.1 years. We used SANS, SAPS, and BPRS to assess psychopathology in Sz patients, showing average scores of 42.45 for SANS (SD:15.30 Range: 7–74), 19.38 for SAPS (SD 11.75; Range: 4–42) and 38.00 for BPRS (SD 7.58; Range: 22–54).

At the time of study, 43 patients received antipsychotic medication (monotherapy with a second-generation antipsychotic in $n = 25$

patients, including $n = 5$ on clozapine; combination therapy with two antipsychotics in $n = 17$ subjects ($n = 9$ with two atypical substances, $n = 8$ with typical and atypical antipsychotics), and one patient was on a combination of clozapin and two other atypicals. 7 subjects did not receive antipsychotic medication.

Healthy controls underwent careful screening for potential exclusion criteria, which were: current or previous psychiatric disorder (including substance abuse/dependence) or current or previous psychiatric or psychotherapeutic treatment. None of the healthy controls had a first-degree relative with psychotic or affective disorders.

General exclusion criteria were: traumatic brain injury or neurological CNS conditions, major untreated general medical conditions (e.g. uncontrolled hypertension or diabetes) and contra-indications to MR imaging.

2.2. Magnetic resonance image (MRI) acquisition

We acquired T1-weighted magnetic resonance imaging scans (5:21 min MPRAGE-sequence, TR 2300 ms, TE 3.03 ms, flip angle 9°, 192 contiguous sagittal slices with an in-plane field of view of 256 mm and a voxel resolution of 1 cubic mm, quadrature head coil) of all 151 subjects using a 3 Tesla Siemens Tim Trio scanner (SIEMENS, Erlangen, Germany).

2.3. Pre-processing

All images were processed and analysed using the CAT12 toolbox (C. Gaser, Structural Brain Mapping Group, Jena University Hospital, Jena, Germany; <http://dbm.neuro.uni-jena.de/cat/>) implemented in SPM12 (Wellcome Trust Centre for Neuroimaging; <http://www.fil.ion.ucl.ac.uk/spm/software/spm12/>). CAT12 served as the platform for all the analyses, as it offers processing pipelines for both voxel-based morphometry as well as surface-based morphometry (incl. cortical thickness and gyrification), allowing us to perform all analysis with this software package.

For processing- and analysis-steps, pre-set parameters in accordance with standard protocol (<http://www.neuro.uni-jena.de/cat12/CAT12-Manual.pdf>) were used, applying default settings unless indicated otherwise.

Processing also included a two-step quality assurance: first, all images were visually inspected for artefacts (prior to pre-processing); secondly, all underwent a statistical quality control for inter-subject homogeneity and overall image quality as included in the CAT12 toolbox (“check homogeneity” function) after segmentation. This second step again included a visual inspection procedure for potential newly introduced artefacts.

2.4. Gyrification analysis

We calculated local (vertex-wise) gyrification index (GI) maps based on the absolute mean curvature approach (Luders et al. 2006). Extraction of the cortical surface (using CAT12 routines) resulted in the construction of a mesh of the central surface (Dahnke et al., 2012), i.e. the surface between the grey matter/CSF border and the grey matter/white matter boundary. We then calculated the local absolute mean curvature of this central surface by averaging the mean curvature values from each vertex point within 3 mm from a given point. In a second step, we applied 15 mm full-width at half maximum (FWHM) smoothing to the GI maps. This method has been applied in previous studies, also with other processing pipelines for cortical surface extraction (Luders et al. 2012; Nenadic et al. 2015a) of our group.

2.5. Cortical thickness analysis

We analysed cortical thickness based on the same algorithm for extraction of the cortical surface implemented in CAT12, as given above for

Table 1
Demographic and clinical data of both groups (SD = standard deviation; Handedness measured using the Edinburgh handedness inventory, IQ estimated using the MWT-B).

	Schizophrenia	Healthy controls
n	51	102
Sex distribution (female/male)	17/34	33/69
Age mean (SD)	35.18 (10.88)	33.15 (9.6)
Age range	21.38–64.85	21.06–60.30
Handedness mean (SD)	58.80 (51.64)	69.99 (35.37)
IQ mean (SD)	105.29 (13.93)	106.57 (11.56)
Duration of illness	8.8 yrs	n/a
SANS mean (SD)	42.45 (15.30)	n/a
SAPS mean (SD)	19.38 (11.75)	n/a
BPRS mean (SD)	38.00 (7.58)	n/a

GI analyses. Here, the central surface as well as cortical thickness are estimated in one step using a projection-based distance measure (Dahnke et al. 2013). The vertex-wise cortical thickness measures were re-sampled and smoothed using a 15 mm FWHM Gaussian kernel.

2.6. Voxel-based morphometry (VBM)

We applied spatial normalisation and segmentation into three voxel classes: grey matter (GM), white matter (WM) and cerebrospinal fluid (CSF) using a segmentation approach based on adaptive maximum a posteriori segmentation and partial volume segmentation. We also determined total intracranial volume (TIV) for all scans. Using modulated normalized GM maps, we tested the hypothesis of regional grey matter volume (GMV) differences. The extracted GM maps were smoothed using an 8 mm FWHM kernel and used for further analysis. We applied a 0.1 absolute masking threshold to the VBM data.

2.7. Statistical analysis

We performed statistical analyses in the CAT12/SPM12 statistical module applying general linear models for each of the three morphometric methods (left and right hemisphere for each of the two surface-based methods, i.e. gyrification and cortical thickness, and whole brain GM analysis for VBM).

Using age and sex as covariates (and for VBM analyses additionally also total intracranial volume, TIV), we tested group differences (increases and decreases of local gyrification in patients, as well as decreases of cortical thickness and decrease of GMV in VBM), applying thresholds of $p < 0.05$ with FWE correction for multiple comparisons. In addition, we transformed all resulting statistical maps to maps of Cohen's d as a measure of effect size using the conversion tool in CAT12.

3. Results

3.1. Gyrification

We found increased gyrification in the Sz group in the bilateral insula region, frontal pole and temporal pole. Results are shown in Fig. 1. There were no significant areas of lower gyrification in Sz compared to healthy controls.

3.2. Cortical thickness

Cortical thickness was significantly reduced ($p < 0.05$ FWE-corrected) in Sz patients in large regions of the medial and orbitofrontal cortices (bilaterally), bilateral dorsolateral and ventrolateral prefrontal cortices, as well as bilateral changes in insular cortices, lateral temporal and inferior occipital cortices, and precuneus. Reduction was particularly apparent in the insula region as well as the temporal pole and the inferior frontal gyrus pars orbitalis.

The Sz group showed higher cortical thickness in precentral and postcentral gyri. Results are summarized in Fig. 2.

3.3. Voxel-based morphometry (VBM)

VBM analysis of the dataset yielded a number of significant clusters ($p < 0.05$, FWE-corrected) of grey matter reduction in Sz. This included clusters in the medial temporal lobe (bilateral, incl. amygdala and hippocampus), medial prefrontal cortex and anterior cingulate cortex (bilateral), right orbitofrontal cortex, insula (bilateral), and cerebellum (right > left).

The local maxima of these clusters were in the right cerebellum (20; -62; -64), clusters including both entorhinal areas and the amygdalae (27 0 -20 and -24 -2 -18), the right posterior insula (38 -6 -2), the right inferior temporal gyrus (57 -63 -15) and the right inferior occipital gyrus (44 -78 -12). Results are summarised in Fig. 3.

Maps for Cohen's d effects sizes for all results are given in Fig. 4.

4. Discussion

This study provides further evidence of altered gyrification in prefrontal and temporal areas in schizophrenia and demonstrates that these alterations only partially overlap with measures of cortical volume or thickness. Gyrification has been proposed as a novel morphometric marker indicating early neurodevelopmental pathology more specifically than previously used methods (Nenadic et al. 2015a; Palaniyappan and Liddle 2012). Our study is the first to directly compare in the same cohort the effects of schizophrenia on gyrification vs. two other commonly used morphometric parameters.

The most prominent hypergyria in our study sample was observed in the insula and the temporal pole. Cortical thickness and GM were altered in the insula, temporal as well as occipital cortex. In addition, thickness was reduced in the frontal pole and inferior prefrontal cortex. For GMV, we additionally report reductions in the cerebellum.

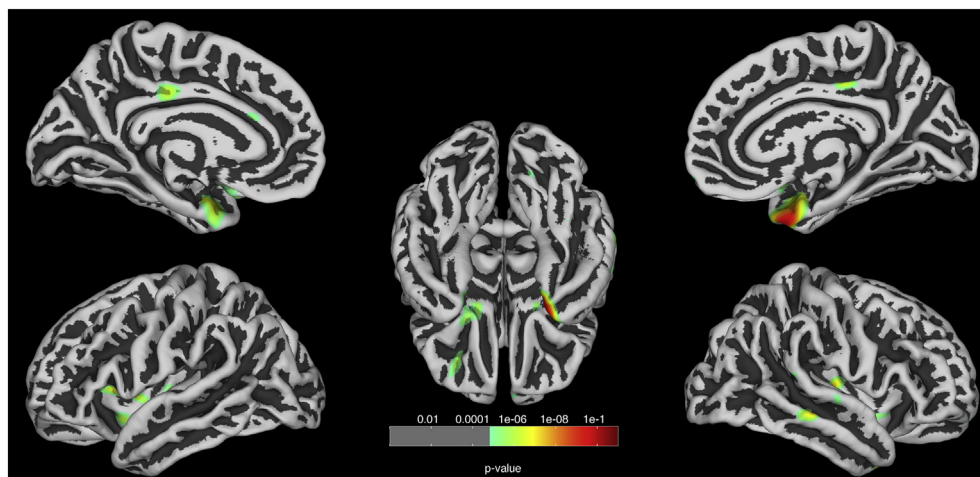


Fig. 1. Gyrification analysis: Comparison of schizophrenia patients vs. healthy controls ($p < 0.05$, FWE corrected). Corrected for age and sex. Results are projected on a central surface. Areas of increased gyrification (green to red scale) in the patient group are highlighted. (For interpretation of the references to color in this figure legend, the reader is referred to the web version of this article.)

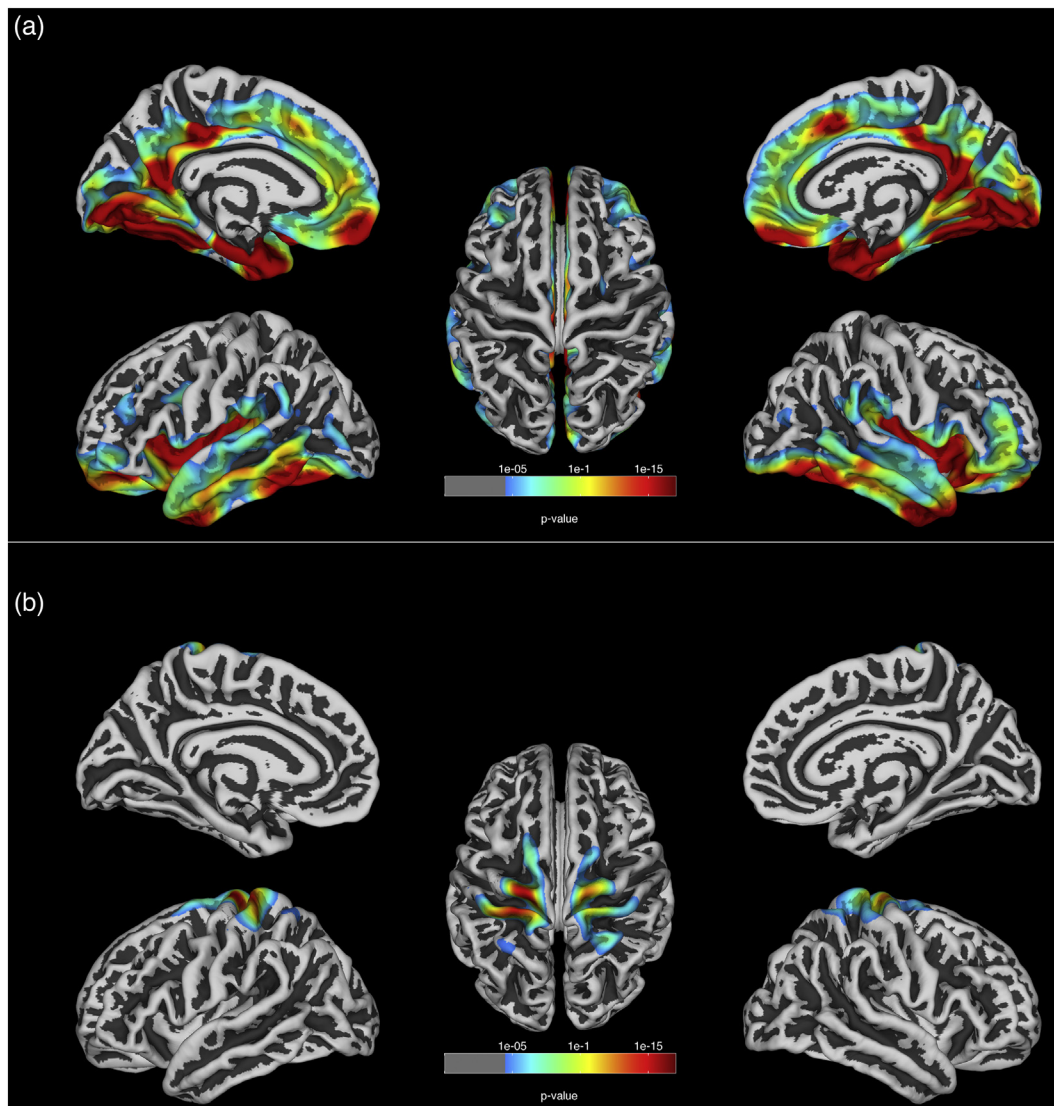


Fig. 2. Cortical thickness analysis: Comparison of schizophrenia patients vs. healthy controls ($p < 0.05$, FWE corrected). Corrected for age and sex. Results are projected on a central surface. Reductions (2a) and increases (2b) in the patient group relative to healthy controls are highlighted with significance-levels visualized on a green to red scale. (For interpretation of the references to color in this figure legend, the reader is referred to the web version of this article.)

The frontopolar cluster of hypergyria coincides with earlier findings in first episode schizophrenia (Sasabayashi et al. 2017a), chronic patients (Palaniyappan et al. 2011) as well as ultra-high-risk cohorts (Lavoie et al. 2014), suggesting prefrontal hypergyria as a potential vulnerability marker of schizophrenia. Prefrontal hypergyrification (compared to non-clinical healthy subjects) was also found in a recent study of both schizophrenia and first-episode non-affective psychosis (Zuliani et al., 2018), lending further support to the relative consistency of frontal lobe gyrification findings. Also, prefrontal hypergyria has been linked to cognitive function in schizophrenia, suggesting an impact in clinically relevant cognitive impairment (Sasabayashi et al. 2017a).

Even stronger and spatially larger extends of hypergyrification were found in the anterior lobe and the insular cortex. These areas are of particular interest, given recent findings in psychosis and cognitive functions, respectively. A recent connectomics study of gyrification has shown changes in gyrification in first episode psychosis in the left insular and cingulate cortex with relevance to clinical outcomes (Palaniyappan et al. 2016). While this study included psychoses other than schizophrenia, it expands on previous studies on a clinically more homogeneous schizophrenia group (Palaniyappan et al. 2015) comparable to our sample. Both prefrontal as well as insular gyrification have been linked to general cognitive ability (Gregory et al. 2016). So

far, it is unclear how specific insular gyrification might be to psychoses or schizophrenia in general. Volume changes in the insula, as studied with conventional VBM, have shown considerable overlap across multiple psychiatric disorders (Goodkind et al. 2015), arguing against disease-specificity.

The most significant differences in gyrification in our sample were, however, in the anterior medial temporal lobes. While increased temporal lobe gyrification was prominent in earlier findings with older techniques, it has subsequently been reported in more recent studies, although the direction and precise localisation of temporal lobe gyrification findings has been inconsistent. When measured as 3D parameter, hypergyrification was reported in high risk individuals (Sasabayashi et al. 2017b) but hypogyrification was found in a chronic sample (Mancini-Marie et al. 2015). A more recent study correlating a polygenic risk score for schizophrenia with gyrification in healthy subjects found no significant correlations in the temporal lobe but parietal cortices (Liu et al. 2017). Our comparison with this recent literature, however, needs to take into account some limitations. The reported inconsistencies might in part be explained by differences in methods to determine gyrification. While our study employs the absolute mean curvature approach (Luders et al. 2006), which has been applied in a range of applications (Besteher et al. 2017; Gaser et al. 2006; Luders

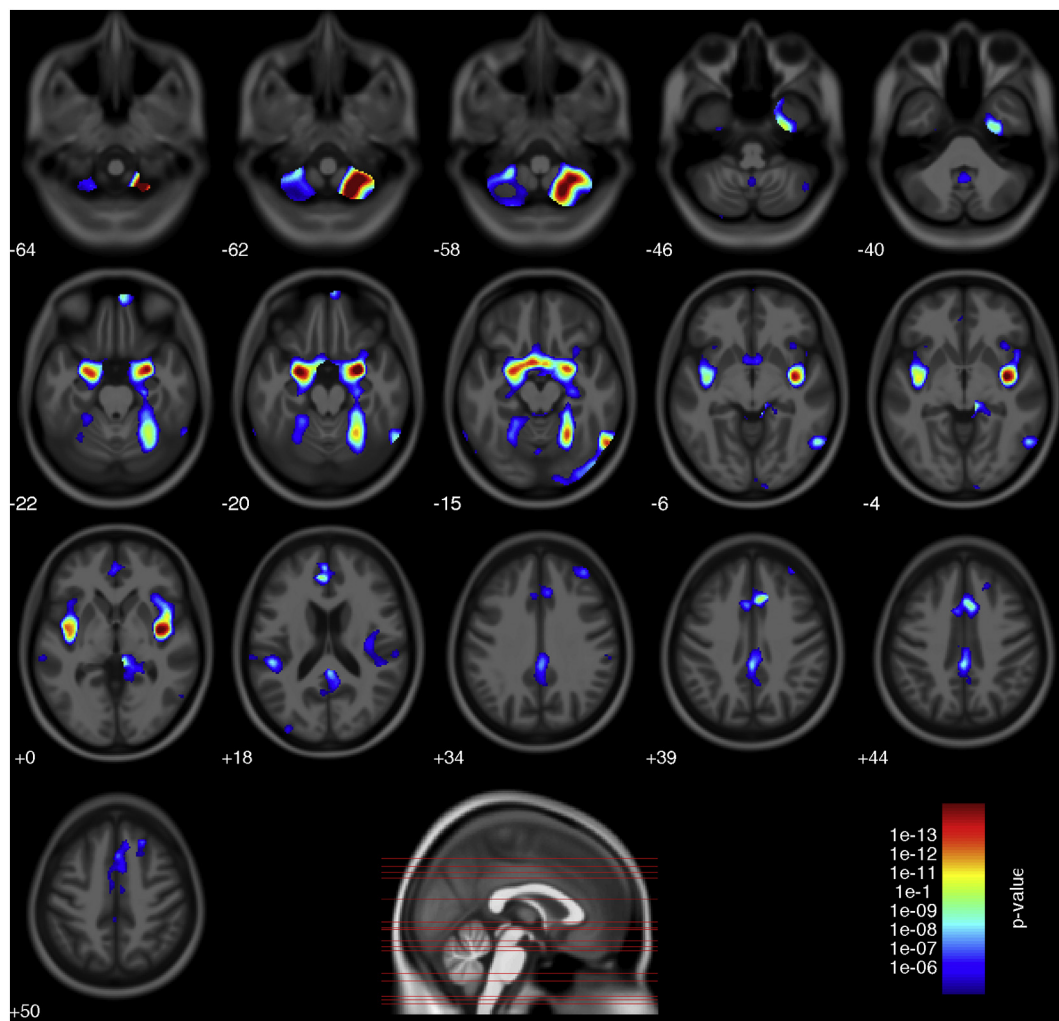


Fig. 3. Voxel-based-morphometry analysis: Comparison of schizophrenia patients vs. healthy controls ($p < 0.05$, FWE corrected). Results are corrected for age, sex and TIV and projected on an average brain image in axial slices. A blue to red scale indicates significance. Bottom: Sagittal view indicating height of axial slices. (For interpretation of the references to color in this figure legend, the reader is referred to the web version of this article.)

et al. 2012; Nenadic et al. 2015a), other studies have employed different approaches (Schaer et al. 2008) and might thus not be completely comparable: In contrast to the local gyrification index (LGI) developed by Schaer et al., the absolute mean curvature approach used in this study is only dependent on the size of the Gaussian smoothing filter, while the LGI additionally depends on the radius of a sphere that is used to estimate the underlying surface area. This radius is influencing the estimated gyrification values. Additionally, absolute mean curvature derived gyrification strongly ($r > 0.9$) correlates to direct measures of surface area on a global as well as on a local level (Luders et al. 2006).

Comparison to our VBM and cortical thickness analyses, which are rather consistent with the recent literature (Gupta et al. 2015) (although there are some discrepancies with older meta-analyses with regards to localisation of volume reductions, e.g. anterior vs. posterior insula (Bora et al. 2012; Glahn et al. 2008), indicate that only a limited subset of areas showing volumetric deficits in schizophrenia also shows evidence of aberrant gyrification. Given that the interpretation of gyrification rests on early developmental disturbance (Zilles et al. 2013), this can be interpreted as a smaller subset of brain areas showing early developmental delay, while volumetric changes might emerge at later stages such as the prodrome or disease onset.

Our findings stress two main aspects. First, disturbed prefrontal gyrification in schizophrenia emerges as a recurrent finding, while changes in temporal lobes and insula are less consistent. Second, the direction of changes varies, especially for temporal lobe findings,

including both increased as well as decreased gyrification. However, unlike volume findings, where loss of volume or cortical thickness might indicate structural deficits, early developmental alterations might result in both hyper- and hypogyria.

The origin of our findings might include both genetic and very early developmental factors. Gyrification has been shown to be genetically influenced in twin studies (Bartley et al. 1997) and a recent study in twins found that 85% of variance in 3D GI was explained by genetic association (Docherty et al. 2015). A link between cytoarchitecture and disturbed macroscopic gyrification is found in maldistributed interstitial white matter neurons (IWMN) (Akbarian et al. 1996). Abnormal IWMN in schizophrenia patients persist in deeper WM layers when compared to controls as remains of the cortical subplate formed during neurodevelopment. This might explain changes in GI as a result of abnormal neuronal tension (Van Essen 1997) and thus link macroscopic changes to a plausible developmental way of action.

The interpretation of our gyrification findings, however, needs to consider some important constraints. While some patterns of changed gyrification, like prefrontal hypergyrification (Sasabayashi et al. 2017a; Zuliani et al., 2018), repeatedly emerge, there are still incongruities across studies and different approaches of GI measurement. Difference in methods, epidemiological sample parameters like sex, medication and chronicity of illness, or features based on the measured property itself (Ronan et al. 2012) might account for divergent results. While our study aimed to correct for differences due to cognitive ability by

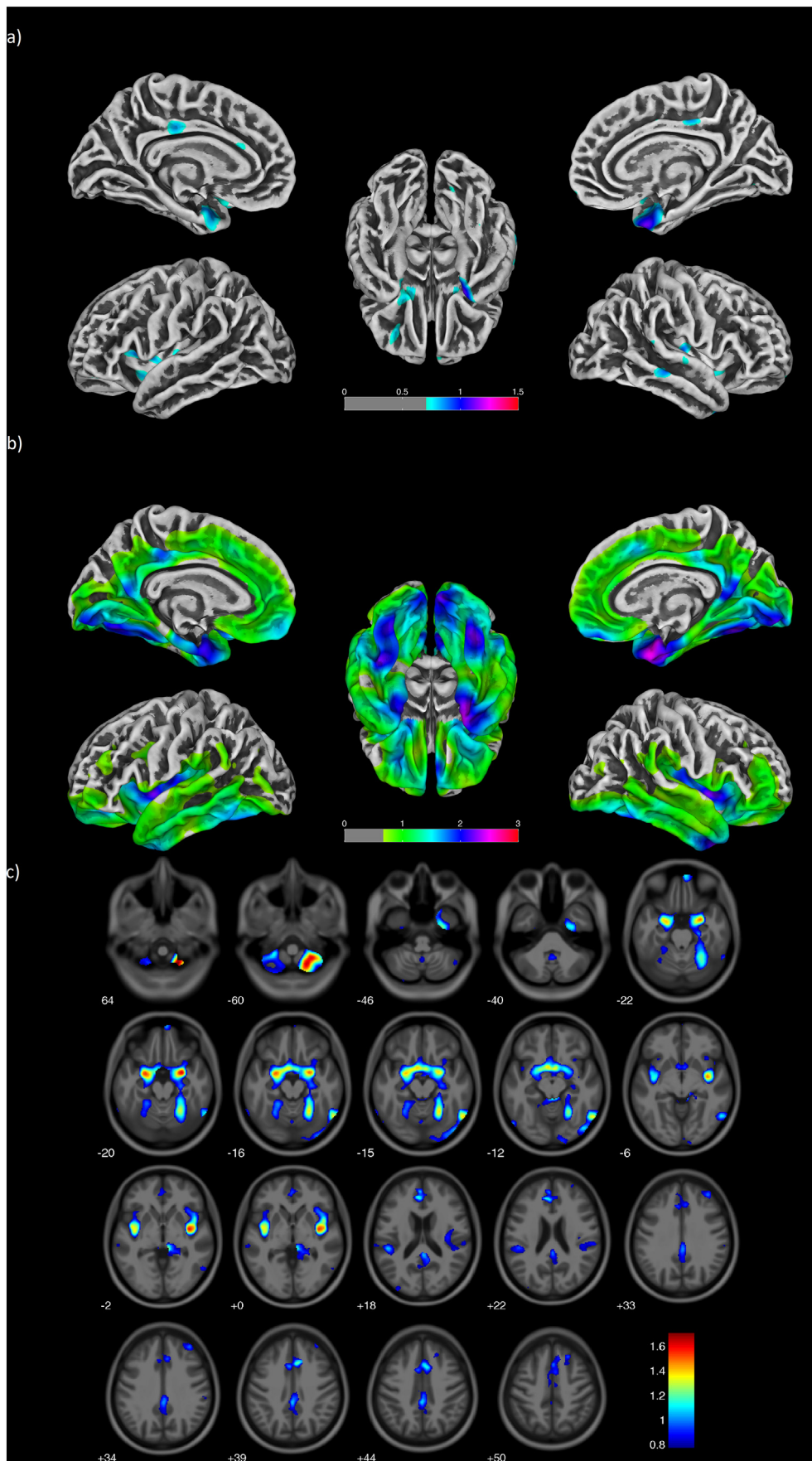


Fig. 4. Maps of effect sizes (Cohens d) of a) increases in gyrification b) decreases in cortical thickness and c) decreases in grey matter volume in schizophrenia patients compared to healthy controls.

matching the samples for IQ, other measures that influence cortical thickness, grey matter volume and possibly gyrification as years of education are not corrected and might affect the outcome. Direct comparison of gyrification with VBM/cortical thickness also needs to consider that differences in effect sizes might obscure additional findings when using conservative thresholds with FWE correction. Also, medication might differentially affect the different measures; while studied for volume-related measures, (Torres et al. 2013; van Haren et al. 2011), there is little data on gyrification. While beyond the scope of this study, we also need to consider that the patient samples, although mostly including chronic patients, was not fully homogeneous regarding the stage of illness.

Taken together, this joint analysis of multiple neuromorphological properties within the same study group advances our understanding of the different facets of brain structural change in schizophrenia. It demonstrates that different aspects of morphology can be separated in a meaningful manner, and how the different morphometric parameters can be used to differentiate effects. Such multi-parameter approaches will aid identification of markers relevant to different aspects of pathophysiology and treatment, and possibly staging of disease.

Acknowledgments

We thank our colleagues at the Department of Psychiatry and Psychotherapy, Jena University Hospital, for their help in initial recruitment and scanning of subjects, especially Kerstin Langbein and Maren Dietzek, as well as the student research assistants contributing to this. We also thank Prof. Heinrich Sauer for his support. Parts of this work were supported by grants of the IZKF Jena (Interdisziplinäres Zentrum für Klinische Forschung of Jena University Hospital) to R.S. and the Friedrich-Schiller-University of Jena and EU to I.N.

Role of funding source

The authors confirm that the funding source had no role in the design, data analysis, or interpretation of the study.

Contributors

R.S. and I.N. designed the study. I.N. obtained funding. R.S. and C.G. conducted statistical and morphometric analyses. I.N. and R.S. contributed to interpretation of data. R.S. wrote the first draft of the manuscript. All authors contributed to and have approved the final manuscript.

Conflicts of interest

The authors declare there are no potential conflicts of interest.

References

- Akbarian, S., Kim, J.J., Potkin, S.G., Hetrick, W.P., Bunney Jr., W.E., Jones, E.G., 1996. Maldistribution of interstitial neurons in prefrontal white matter of the brains of schizophrenic patients. *Arch. Gen. Psychiatry* 53, 425–436.
- Armstrong, E., Schleicher, A., Omran, H., Curtis, M., Zilles, K., 1995. The ontogeny of human gyrification. *Cereb. Cortex* 5, 56–63.
- Bartley, A.J., Jones, D.W., Weinberger, D.R., 1997. Genetic variability of human brain size and cortical gyral patterns. *Brain* 120 (Pt 2), 257–269.
- Besteher, B., Wagner, G., Koch, K., Schachtzabel, C., Reichenbach, J.R., Schlosser, R., Sauer, H., Schultz, C.C., 2016. Pronounced prefronto-temporal cortical thinning in schizophrenia: neuroanatomical correlate of suicidal behavior? *Schizophr. Res.* 176, 151–157.
- Besteher, B., Gaser, C., Spalthoff, R., Nenadic, I., 2017. Associations between urban upbringing and cortical thickness and gyrification. *J. Psychiatr. Res.* 95, 114–120.
- Bora, E., Fornito, A., Yucel, M., Pantelis, C., 2012. The effects of gender on grey matter abnormalities in major psychoses: a comparative voxelwise meta-analysis of schizophrenia and bipolar disorder. *Psychol. Med.* 42, 295–307.
- Chan, R.C., Di, X., McAlonan, G.M., Gong, Q.Y., 2011. Brain anatomical abnormalities in high-risk individuals, first-episode, and chronic schizophrenia: an activation likelihood estimation meta-analysis of illness progression. *Schizophr. Bull.* 37, 177–188.
- Dahnke, R., Yotter, R.A., Gaser, C., 2013. Cortical thickness and central surface estimation. *NeuroImage* 65, 336–348.
- Docherty, A.R., Hagler Jr., D.J., Panizzon, M.S., Neale, M.C., Eyer, L.T., Fennema-Notestine, C., Franz, C.E., Jak, A., Lyons, M.J., Rinker, D.A., Thompson, W.K., Tsuang, M.T., Dale, A.M., Kremen, W.S., 2015. Does degree of gyrification underlie the phenotypic and genetic associations between cortical surface area and cognitive ability? *NeuroImage* 106, 154–160.
- Edlin, J.M., Leppanen, M.L., Fain, R.J., Hacklander, R.P., Hanaver-Torrez, S.D., Lyle, K.B., 2015. On the use (and misuse?) of the Edinburgh Handedness Inventory. *Brain Cogn.* 94, 44–51.
- Gaser, C., Luders, E., Thompson, P.M., Lee, A.D., Dutton, R.A., Geaga, J.A., Hayashi, K.M., Bellugi, U., Galaburda, A.M., Korenberg, J.R., Mills, D.L., Toga, A.W., Reiss, A.L., 2006. Increased local gyrification mapped in Williams syndrome. *NeuroImage* 33, 46–54.
- Glahn, D.C., Laird, A.R., Ellison-Wright, I., Thelen, S.M., Robinson, J.L., Lancaster, J.L., Bullmore, E., Fox, P.T., 2008. Meta-analysis of gray matter anomalies in schizophrenia: application of anatomic likelihood estimation and network analysis. *Biol. Psychiatry* 64, 774–781.
- Goldman, A.L., Pezawas, L., Mattay, V.S., Fischl, B., Verchinski, B.A., Chen, Q., Weinberger, D.R., Meyer-Lindenberg, A., 2009. Widespread reductions of cortical thickness in schizophrenia and spectrum disorders and evidence of heritability. *Arch. Gen. Psychiatry* 66, 467–477.
- Goodkind, M., Eickhoff, S.B., Oathes, D.J., Jiang, Y., Chang, A., Jones-Hagata, L.B., Ortega, B.N., Zaiko, Y.V., Roach, E.L., Korgaonkar, M.S., Grieve, S.M., Galatzer-Levy, I., Fox, P.T., Etkin, A., 2015. Identification of a common neurobiological substrate for mental illness. *JAMA Psychiat.* 72, 305–315.
- Gregory, M.D., Kippenhan, J.S., Dickinson, D., Carrasco, J., Mattay, V.S., Weinberger, D.R., Berman, K.F., 2016. Regional variations in brain gyrification are associated with general cognitive ability in humans. *Curr. Biol.* 26, 1301–1305.
- Gupta, C.N., Calhoun, V.D., Rachakonda, S., Chen, J., Patel, V., Liu, J., Segall, J., Franke, B., Zwiers, M.P., Arias-Vasquez, A., Buitelaar, J., Fisher, S.E., Fernandez, G., van Erp, T.G., Potkin, S., Ford, J., Mathalon, D., McEwen, S., Lee, H.J., Mueller, B.A., Greve, D.N., Andreassen, O., Agartz, I., Gollub, R.L., Sponheim, S.R., Ehrlich, S., Wang, L., Pearson, G., Glahn, D.C., Sprooten, E., Mayer, A.R., Stephen, J., Jung, R.E., Canive, J., Bustillo, J., Turner, J.A., 2015. Patterns of gray matter abnormalities in schizophrenia based on an international mega-analysis. *Schizophr. Bull.* 41, 1133–1142.
- de Haan, L., Bakker, J.M., 2004. Overview of neuropathological theories of schizophrenia: from degeneration to progressive developmental disorder. *Psychopathology* 37, 1–7.
- van Haren, N.E., Schnack, H.G., Cahn, W., van den Heuvel, M.P., Lepage, C., Collins, L., Evans, A.C., Hulshoff Pol, H.E., Kahn, R.S., 2011. Changes in cortical thickness during the course of illness in schizophrenia. *Arch. Gen. Psychiatry* 68, 871–880.
- Haukvik, U.K., Schaer, M., Nesvag, R., McNeil, T., Hartberg, C.B., Jonsson, E.G., Eliez, S., Agartz, I., 2012. Cortical folding in Broca's area relates to obstetric complications in schizophrenia patients and healthy controls. *Psychol. Med.* 42, 1329–1337.
- Kubota, M., Miyata, J., Yoshida, H., Hirao, K., Fujiwara, H., Kawada, R., Fujimoto, S., Tanaka, Y., Sasamoto, A., Sawamoto, N., Fukuyama, H., Murai, T., 2011. Age-related cortical thinning in schizophrenia. *Schizophr. Res.* 125, 21–29.
- Lavoie, S., Bartholomeuz, C.F., Nelson, B., Lin, A., McGorry, P.D., Velakoulis, D., Whittle, S.L., Yung, A.R., Pantelis, C., Wood, S.J., 2014. Sulcogyral pattern and sulcal count of the orbitofrontal cortex in individuals at ultra high risk for psychosis. *Schizophr. Res.* 154, 93–99.
- Liu, B., Zhang, X., Cui, Y., Qin, W., Tao, Y., Li, J., Yu, C., Jiang, T., 2017. Polygenic risk for schizophrenia influences cortical gyrification in 2 independent general populations. *Schizophr. Bull.* 43, 673–680.
- Luders, E., Thompson, P.M., Narr, K.L., Toga, A.W., Jancke, L., Gaser, C., 2006. A curvature-based approach to estimate local gyrification on the cortical surface. *NeuroImage* 29, 1224–1230.
- Luders, E., Kurth, F., Mayer, E.A., Toga, A.W., Narr, K.L., Gaser, C., 2012. The unique brain anatomy of meditation practitioners: alterations in cortical gyrification. *Front. Hum. Neurosci.* 6, 34.
- Mancini-Marie, A., Yoon, U., Jimenez, J., Fahim, C., Potvin, S., Grant, J.A., Laverdure-Dupont, D., Dube, A.A., Betrisey, C., Rainville, P., Evans, A.C., Stip, E., Mendrek, A., 2015. Sex, Age, Symptoms and Illness Duration and their Relation with Gyrification Index in Schizophrenia (Clin Schizophr Relat Psychoses).
- McIntosh, A.M., Moorhead, T.W., McKirdy, J., Hall, J., Sussmann, J.E., Stanfield, A.C., Harris, J.M., Johnstone, E.C., Lawrie, S.M., 2009. Prefrontal gyral folding and its cognitive correlates in bipolar disorder and schizophrenia. *Acta Psychiatr. Scand.* 119, 192–198.
- Nanda, P., Tandon, N., Mathew, I.T., Giakoumatos, C.I., Abhishekh, H.A., Clementz, B.A., Pearlson, G.D., Sweeney, J., Tammimga, C.A., Keshavan, M.S., 2014. Local gyrification index in probands with psychotic disorders and their first-degree relatives. *Biol. Psychiatry* 76, 447–455.
- Nenadic, I., Maitra, R., Dietzek, M., Langbein, K., Smesny, S., Sauer, H., Gaser, C., 2015a. Prefrontal gyrification in psychotic bipolar I disorder vs. schizophrenia. *J. Affect. Disord.* 185, 104–107.
- Nenadic, I., Maitra, R., Langbein, K., Dietzek, M., Lorenz, C., Smesny, S., Reichenbach, J.R., Sauer, H., Gaser, C., 2015b. Brain structure in schizophrenia vs. psychotic bipolar I disorder: a VBM study. *Schizophr. Res.* 165, 212–219.
- Nesvag, R., Lawyer, G., Varnas, K., Fjell, A.M., Walhovd, K.B., Frigessi, A., Jonsson, E.G., Agartz, I., 2008. Regional thinning of the cerebral cortex in schizophrenia: effects of diagnosis, age and antipsychotic medication. *Schizophr. Res.* 98, 16–28.
- Nesvag, R., Schaer, M., Haukvik, U.K., Westlye, L.T., Rimol, L.M., Lange, E.H., Hartberg, C.B., Ottet, M.C., Melle, I., Andreassen, O.A., Jonsson, E.G., Agartz, I., Eliez, S., 2014. Reduced brain cortical folding in schizophrenia revealed in two independent samples. *Schizophr. Res.* 152, 333–338.
- Oldfield, R.C., 1971. The assessment and analysis of handedness: the Edinburgh inventory. *Neuropsychologia* 9, 97–113.
- Palaniyappan, L., Liddle, P.F., 2012. Aberrant cortical gyrification in schizophrenia: a surface-based morphometry study. *J. Psychiatry Neurosci.* 37, 399–406.
- Palaniyappan, L., Mallikarjun, P., Joseph, V., White, T.P., Liddle, P.F., 2011. Folding of the prefrontal cortex in schizophrenia: regional differences in gyrification. *Biol. Psychiatry* 69, 974–979.
- Palaniyappan, L., Park, B., Balain, V., Dangi, R., Liddle, P., 2015. Abnormalities in structural covariance of cortical gyrification in schizophrenia. *Brain Struct. Funct.* 220, 2059–2071.
- Palaniyappan, L., Marques, T.R., Taylor, H., Mondelli, V., Reinders, A., Bonaccorso, S., Giordano, A., Diforti, M., Simmons, A., David, A.S., Pariante, C.M., Murray, R.M., Dazzan, P., 2016. Globally efficient brain organization and treatment response in psychosis: a connectomic study of gyrification. *Schizophr. Bull.* 42, 1446–1456.
- Rakic, P., 2009. Evolution of the neocortex: a perspective from developmental biology. *Nat. Rev. Neurosci.* 10, 724–735.

- Rapoport, J.L., Giedd, J.N., Gogtay, N., 2012. Neurodevelopmental model of schizophrenia: update 2012. *Mol. Psychiatry* 17, 1228–1238.
- Ronan, L., Voets, N.L., Hough, M., Mackay, C., Roberts, N., Suckling, J., Bullmore, E., James, A., Fletcher, P.C., 2012. Consistency and interpretation of changes in millimeter-scale cortical intrinsic curvature across three independent datasets in schizophrenia. *NeuroImage* 63, 611–621.
- Sasabayashi, D., Takayanagi, Y., Nishiyama, S., Takahashi, T., Furuichi, A., Kido, M., Nishikawa, Y., Nakamura, M., Noguchi, K., Suzuki, M., 2017a. Increased frontal gyrification negatively correlates with executive function in patients with first-episode schizophrenia. *Cereb. Cortex* 27, 2686–2694.
- Sasabayashi, D., Takayanagi, Y., Takahashi, T., Koike, S., Yamasue, H., Katagiri, N., Sakuma, A., Obara, C., Nakamura, M., Furuichi, A., Kido, M., Nishikawa, Y., Noguchi, K., Matsumoto, K., Mizuno, M., Kasai, K., Suzuki, M., 2017b. Increased occipital gyrification and development of psychotic disorders in individuals with an at-risk mental state: a multicenter study. *Biol. Psychiatry* 82, 737–745.
- Schaer, M., Cuadra, M.B., Tamarit, L., Lazeyras, F., Eliez, S., Thiran, J.P., 2008. A surface-based approach to quantify local cortical gyrification. *IEEE Trans. Med. Imaging* 27, 161–170.
- Shah, C., Zhang, W., Xiao, Y., Yao, L., Zhao, Y., Gao, X., Liu, L., Liu, J., Li, S., Tao, B., Yan, Z., Fu, Y., Gong, Q., Lui, S., 2016. Common pattern of gray-matter abnormalities in drug-naive and medicated first-episode schizophrenia: a multimodal meta-analysis. *Psychol. Med.* 1–13.
- Torres, U.S., Portela-Oliveira, E., Borgwardt, S., Busatto, G.F., 2013. Structural brain changes associated with antipsychotic treatment in schizophrenia as revealed by voxel-based morphometric MRI: an activation likelihood estimation meta-analysis. *BMC Psychiatry* 13, 342.
- Van Essen, D.C., 1997. A tension-based theory of morphogenesis and compact wiring in the central nervous system. *Nature* 385, 313–318.
- Vogeley, K., Schneider-Axmann, T., Pfeiffer, U., Tepest, R., Bayer, T.A., Bogerts, B., Honer, W.G., Falkai, P., 2000. Disturbed gyrification of the prefrontal region in male schizophrenic patients: a morphometric postmortem study. *Am. J. Psychiatry* 157, 34–39.
- Zilles, K., Armstrong, E., Schleicher, A., Kretschmann, H.J., 1988. The human pattern of gyrification in the cerebral cortex. *Anat. Embryol. (Berl)* 179, 173–179.
- Zilles, K., Palomero-Gallagher, N., Amunts, K., 2013. Development of cortical folding during evolution and ontogeny. *Trends Neurosci.* 36, 275–284.
- Zuliani, R., Delvecchio, G., Bonivento, C., Cattarinussi, G., Perlini, C., Bellani, M., Marinelli, V., Rossetti, M.G., Lasalvia, A., McIntosh, A., Lawrie, S.M., Balestrieri, M., Ruggeri, M., Brambilla, P., Group, P.V., 2018. Increased gyrification in schizophrenia and non affective first episode of psychosis. *Schizophr. Res.* 193, 269–275.