

Structural Brain Changes in Tinnitus

M. Mühlau¹, J. P. Rauschecker², E. Oestreicher³, C. Gaser⁴,
M. Röttinger⁵, A. M. Wohlschläger^{1,5,6}, F. Simon¹, T. Etgen¹,
B. Conrad¹ and D. Sander¹

¹Department of Neurology, Technische Universität München, D-81675 München, Germany, ²Department of Physiology and Biophysics, Georgetown University Medical Center, Washington, DC 20007, USA, ³Department of Otolaryngology, Technische Universität D-81675 München, Germany, ⁴Department of Psychiatry, University of Jena, Jena D-07740, Germany, ⁵Department of Radiology, Technische Universität München, D-81675 München, Germany and ⁶Nuklearmedizinische Klinik und Poliklinik, Technische Universität München, München D-81675, Germany

Tinnitus is a common but poorly understood disorder characterized by ringing or buzzing in the ear. Central mechanisms must play a crucial role in generating this auditory phantom sensation as it persists in most cases after severing the auditory nerve. One hypothesis states that tinnitus is caused by a reorganization of tonotopic maps in the auditory cortex, which leads to an overrepresentation of tinnitus frequencies. Moreover, the participation of the limbic system in generating tinnitus has been postulated. Here we aimed at identifying brain areas that display structural change in tinnitus. We compared tinnitus sufferers with healthy controls by using high-resolution magnetic resonance imaging and voxel-based morphometry. Within the auditory pathways, we found gray-matter increases only at the thalamic level. Outside the auditory system, gray-matter decrease was found in the subcallosal region including the nucleus accumbens. Our results suggest that reciprocal involvement of both sensory and emotional areas are essential in the generation of tinnitus.

Keywords: medial geniculate nucleus, nucleus accumbens, subcallosal area, tinnitus, voxel-based morphometry

Introduction

Tinnitus is a common and often debilitating hearing disorder (Lockwood and others 2002). In addition, the study of tinnitus is of considerable interest for the understanding of basic brain mechanisms of hearing, especially with regard to reorganization and plasticity in the adult brain. Tinnitus is referred to as a phantom sensation because sound is perceived in the absence of a physical sound source and, in this respect, has also been compared with phantom pain (Jastreboff 1990; Flor and others 1995; Mühlnickel and others 1998; Rauschecker 1999). Despite extensive research, the neural mechanisms that cause tinnitus remain largely hypothetical (Eggermont and Roberts 2004). Tinnitus often arises through aging or from loud-noise exposure, both of which lead to loss of hair cells in the inner ear and subsequent hearing impairment.

However, several findings challenge purely cochlear models of tinnitus: 1) Tinnitus persists in most cases after severing of the eighth cranial nerve following surgical treatment of acoustic neuroma (Wiegand and others 1996; Andersson and others 1997). 2) Many patients with hearing loss do not suffer from chronic tinnitus (Lockwood and others 2002). 3) Psychometrically measured tinnitus loudness hardly correlates with tinnitus-related distress (Henry and Meikle 2000) or outcome of the treatment (Jastreboff and others 1994). 4) Most people occasionally experience “ringing in their ears” not only after

irritation of the auditory system, such as after listening to loud music, but also in near-to-absolute silence (Heller and Bergman 1953).

Taken together, these observations have led to the view that tinnitus is caused by both peripheral and central mechanisms: 1) peripheral injury, 2) a reorganization of central auditory pathways, and 3) changes in parts of the limbic system that perform a valuation of the emotional content of sensory experiences. This hypothesis was first put forward in a comprehensive model by Jastreboff (1990). However, the exact localization of brain changes with tinnitus has remained controversial.

Animal studies point to different brain structures. Salicylate-induced tinnitus goes along with an increase of the spontaneous activity and the emergence of a bursting type of activity in the external nucleus of the inferior colliculus (Chen and Jastreboff 1995; Kwon and others 1999), whereas intense sound exposure leads to hyperactivity in the dorsal cochlear nucleus (Kaltenbach and others 2005). Moreover, tinnitus-evoking manipulations result in an increased activity of various structures in the auditory and limbic system, as revealed by various activity-dependent assays, such as the cytoskeleton-associated protein Arg3.1, [¹⁴C]2-deoxyglucose, or c-fos expression (Wallhäusser-Franke and others 1996, 2003; Mahlke and Wallhäusser-Franke 2004).

In humans, functional imaging studies on tinnitus are hindered by the lack of an adequate control condition and have pointed to different structures within the auditory pathways. Changes at the level of the auditory cortex have been suggested by work using positron emission tomography (PET) (Arnold and others 1996; Lockwood and others 1998), magnetoencephalography (Mühlnickel and others 1998), and functional magnetic resonance imaging (MRI) (Giraud and others 1999; Mirz and others 1999), whereas the inferior colliculus has been implicated by others (Melcher and others 2000). Clear evidence for changes in a specific location of the limbic system is even sparser: Only 1 PET study so far has demonstrated abnormal activity within limbic structures, but only with a resolution insufficient to unequivocally identify a particular region and only in the rare form of tinnitus that can be altered by oral facial movements (Lockwood and others 1998).

This lack of decisive knowledge about the locus of tinnitus-related changes in the brain has held up an investigation of the mechanisms leading to tinnitus and, hence, approaches to successful treatment. We decided to employ a technique that is capable of pinpointing region-specific changes and that, on this basis, has already led to new therapeutic options in

a particular type of headache (May and others 1999; Leone and others 2004). This technique, voxel-based morphometry (VBM), is based on the use of high-resolution MRI revealing alterations in the concentration or volume of gray and white matter at the group level (Ashburner and Friston 2000; Good and others 2001). Although the technique is aimed primarily at revealing alterations in the concentration or volume of gray and white matter, several studies have demonstrated that these structural changes are directly related to functional changes in brain activity (Gaser and Schlaug 2003; Draganski and others 2004).

Materials and Methods

Participants

In accordance with the Declaration of Helsinki 2000, all subjects were informed about the purpose of the study before giving their written consent. The study had been approved by the local Ethics Committee of the Faculty of Medicine at the Technical University of Munich. Participants were recruited from tinnitus sufferers who consulted our outpatient ear, nose, and throat department between 2001 and 2003. Neither did the 28 tinnitus sufferers have a hearing loss that was detectable with standard audiometric testing (i.e., thresholds were <25 dB hearing level for all 6 standard audiometric frequencies) nor did any of them have a history of noise trauma or chronic noise exposure. Further features of the tinnitus sufferers are summarized in Table 1 including tinnitus-related distress as determined with a standard German questionnaire ("Tinnitus-Fragebogen") (Goebel and Hiller 1994; Hiller and others 1994). Apart from tinnitus, participants had neither audiological complaints (e.g., hyperacusis) nor neurological or psychiatric disorders. No patient localized his tinnitus exclusively to one side. Seven patients negated any lateralization of their sound. Thirteen patients had their tinnitus "in both ears" or "in the head" but could somehow distinguish a lateralization (5 to the right, 8 to the left). The remaining 8 patients could clearly indicate one side as paramount to the other (4 right > left, 4 left > right). The tinnitus percept was described as whistling (16), ringing (2), buzzing (9), or hissing (1). The pitch of the tinnitus was described as high in most (24) cases (intermediate, 3; low, 1). Eight patients heard more than 1 sound. Twenty-eight unaffected healthy controls were matched for age and sex in a pairwise manner (mean age: tinnitus sufferers, 40; controls, 39; ranges of both groups: 26–53, 15 females in each group).

Magnetic Resonance Imaging

Imaging was performed using a 1.5-T Siemens scanner (Magnetom Symphony) with a standard 8-channel birdcage head coil. A 3-dimensional, structural, high-resolution T_1 -weighted MRI using a magnetization-prepared rapid gradient echo sequence was acquired on each subject (sagittal plane; picture matrix, 256 × 256 mm; time repetition, 1520 ms; echo time, 3.93 ms; time for inversion, 800 ms; flip angle, 15°; distance factor, 50%; number of slices, 160; slice thickness, 1 mm). These scans

Table 1
Characterization of the tinnitus group

Item (maximal possible score)	Min.	Max.	Median	Mean	SD
1 Emotional distress (24)	0	18	8	7	5
2 Cognitive distress (16)	0	14	5	5	4
3 Em. + Cog. distress (40)	0	32	13	12	8
4 Intrusiveness (16)	0	15	7	7	4
5 Auditory complaints (14)	0	9	1	2	2
6 Sleep disturbances (8)	0	6	2	2	2
7 Somatic complaints (6)	0	5	0	1	1
8 Sum of items 1, 2, 4–7 (84)	1	58	26	25	16
9 Subjective loudness (10)	2	10	5	5	2
10 Duration in months	7	240	37	53	52

Note: Items 1–8 correspond to a standard German questionnaire ("Tinnitus-Fragebogen") (Goebel and Hiller 1994; Hiller and others 1994). Em. + Cog., emotional and cognitive; Min., minimum; Max., maximum; SD, standard deviation.

were screened by a neuroradiologist who detected neither abnormal nor unusual findings.

Data Processing and Statistical Analysis

SPM2 software (Wellcome Department of Cognitive Neurology, London, UK) was applied for data analysis. The main idea of VBM (Ashburner and Friston 2000; Good and others 2001) comprises the following steps: 1) spatial normalization of all images to a standardized anatomical space to allow spatial averaging, 2) segmentation of images into gray and white matter and cerebrospinal fluid, and 3) comparison of local gray-matter volume or concentration across the whole brain. Image preprocessing was performed as previously described (Good and others 2001) using study-specific prior probability maps. The resulting gray-matter images were smoothed with a Gaussian kernel of 8 mm full width at half maximum. The whole procedure yielded 2 images per subject, namely, gray-matter images that were either modulated or unmodulated. Analysis of modulated data tests for regional differences in the absolute amount (volume) of gray matter, whereas analysis of unmodulated data tests for regional differences in concentration of gray matter (per unit volume in native space) (Good and others 2001). In this study, we analyzed both modulated and unmodulated data. Voxel-by-voxel t -tests using the general linear model (Friston 1996) were used to detect gray-matter differences between tinnitus sufferers and control subjects. To account for unequal variance between both groups, we applied non-sphericity correction as implemented in SPM2. For the statistical analysis, we excluded all voxels with a gray-matter value less than 0.2 (maximum value: 1) to avoid possible edge effects around the border between gray and white matter and to include only voxels with sufficient gray matter. Statistical analyses for changes within the auditory system were corrected for the volume of the auditory system. For this purpose, we defined a region of interest that included the ventral and dorsal cochlear nuclei (sphere radius, 5 mm; Montreal-Neurological-Institute (MNI)-coordinates, $\pm 10, -38, -45$), superior olivary complex (sphere radius, 5 mm; MNI-coordinates, $\pm 13, -35, -41$), inferior colliculus (sphere radius, 5 mm; MNI-coordinates, $\pm 6, -33, -11$), medial geniculate nucleus (MGN) (sphere radius, 8 mm; MNI-coordinates, $\pm 17, -24, -2$), as well as the primary and secondary auditory cortices corresponding to Brodmann areas 41, 42, and 22 (defined with an extension of SPM2, the WFU-Pick Atlas [Maldjian and others 2003]). Statistical analyses for changes outside the auditory system were corrected for the volume of the whole brain. We applied a height threshold (voxel level) of $P < 0.05$ (corrected for multiple comparisons using false discovery rate [FDR] [Genovese and others 2002]). In addition, a spatial extent threshold (cluster level) of $P < 0.05$ (corrected for multiple comparisons [Friston and others 1996]) was applied.

Results

Whole-Brain Analysis

A highly significant decrease of gray-matter volume was identified in the subcallosal area (Fig. 1A,B; thresholded at $P < 0.05$, corrected at both voxel and cluster level; Z value of peak voxel, 4.9; P value of peak voxel corrected at the voxel level using FDR, 0.015; P value corrected at the cluster level, 0.0002). No other brain regions showed increases or decreases of either gray-matter volume or concentration that were significant at this P level. It was particularly surprising that no changes were found within the auditory system. We therefore performed a region-of-interest analysis.

Region-of-Interest Analysis

Within the auditory system, we encountered significant structural differences between tinnitus sufferers and normal controls only at the thalamic level (Fig. 2), although auditory brain stem structures and the auditory cortex were equally included in our analysis. The right posterior thalamus including the MGN showed an increase in gray-matter concentration (Fig. 1A,B;

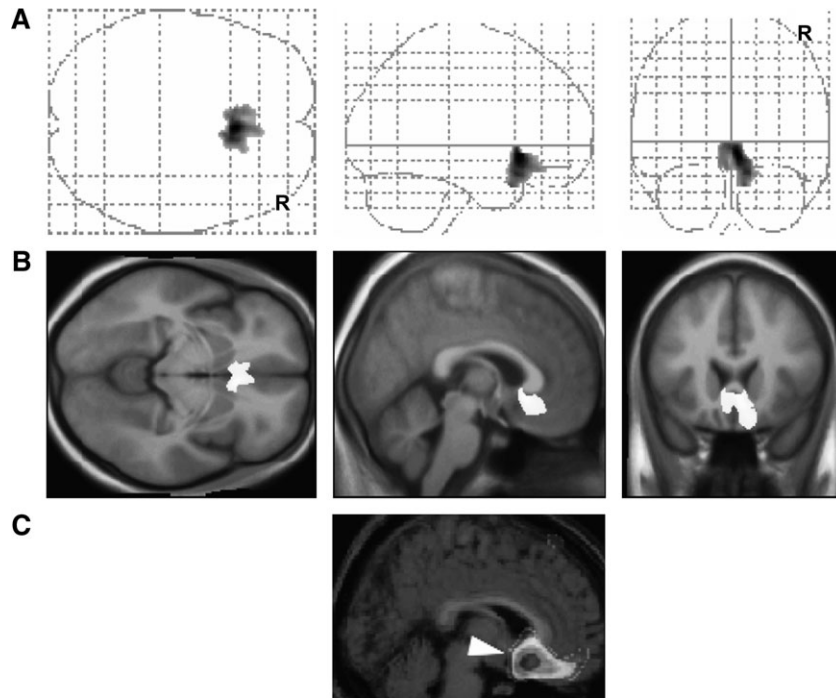


Figure 1. Gray-matter volume decreases. Changes throughout the whole brain are displayed. (A) Maximum intensity projection with a threshold of $P < 0.05$ corrected at both voxel and cluster level. (B) Gray-matter decrease of the subcallosal area is projected onto the study-specific averaged T_1 image. MNI-coordinates of peak value: $x = 4, y = 20, z = -6$; cluster size: 5234 voxels. (C) Data from Blood and others (1999) are shown for comparison. The subcallosal area displays significant negative correlation of regional cerebral blood flow with unpleasant emotions evoked by increasing musical dissonance.

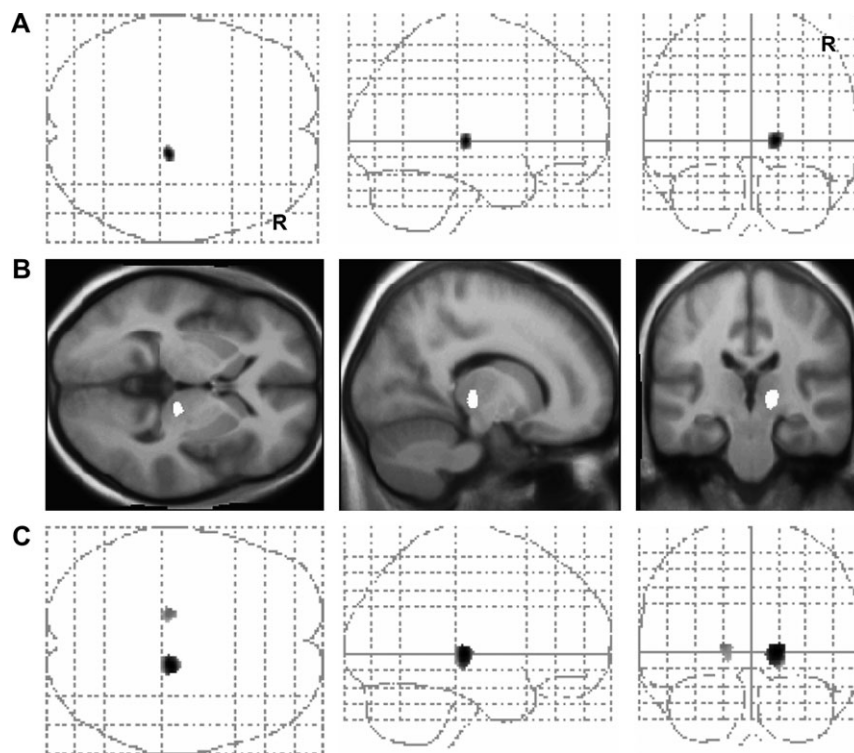


Figure 2. Gray-matter concentration increases. Only changes within the region of interest defined for the auditory system are displayed. (A) Maximum intensity projection with a threshold of $P < 0.05$ (corrected) at both voxel and cluster level. (B) Gray-matter increase of the right posterior thalamus including the MGN is projected onto the study-specific averaged T_1 image. MNI-coordinates of the peak value: $x = 15, y = -23, z = -1$; cluster size: 388 voxels. (C) Maximum intensity projection with the lower threshold of $P < 0.05$ (uncorrected) and the extent threshold of 30 contiguous voxels shows additional gray-matter increase only of the left posterior thalamus. MNI-coordinates of the peak value: $x = -15, y = -23, z = 5$; Z value, 2.4; cluster extent, 360 voxels.

thresholded at $P < 0.05$, corrected at both voxel and cluster level; Z value of peak voxel, 3.7; P value corrected at the voxel level using FDR, 0.04; P value corrected at the cluster level, 0.02). After relaxing the significance threshold to $P < 0.05$ uncorrected (extent threshold: 30 voxels), concentration increases surfaced also in the left posterior thalamus but not in any other structures of the auditory system (Fig. 2C).

Discussion

Although tinnitus is often considered a heterogeneous condition, all tinnitus sufferers share the complaint of an auditory phantom sensation. In terms of brain mechanisms of tinnitus, the present data suggest that, as a group, tinnitus sufferers share a highly significant gray-matter decrease in the subcallosal area. In addition, an increase of gray-matter concentration was found in the auditory thalamus of the tinnitus group.

The finding of structural tinnitus-related changes in the subcallosal region is intriguing for a variety of reasons: Activity in the subcallosal region is correlated with unpleasant emotions elicited by varying amounts of musical dissonance, exactly at the site where gray-matter decreases were identified by our results (Fig. 1C) (Blood and others 1999). Another study reports activation in the subcallosal region by aversive sounds (Zald and Pardo 2002). Furthermore, this area in the “limbic-related” (or paralimbic) ventral striatum, which includes the nucleus accumbens (NAc), plays a crucial role in the formation of adaptive behavioral responses to environmental stimuli. In humans, the NAc is active during instrumental as well as Pavlovian conditioning (O’Doherty and others 2004). In animal studies, the NAc has been shown to be involved in reward-directed as well as avoidance learning (McCullough and others 1993; Schultz 2004). Lesions of the NAc in rats impair the habituation to noise bursts preceded by a warning sound (McCullough and others 1993). The NAc receives glutamatergic input from the amygdala (Koob 2000) and serotonergic input from the brain stem raphe nuclei (Brown and Molliver 2000), which are involved in the regulation of sleep and arousal. Interconnected parallel circuits exist between NAc and thalamus, in particular the thalamic reticular nucleus (TRN) (O’Donnell and others 1997), where the NAc can exert an inhibitory gating influence over the thalamocortical relay. Decreased gray-matter volume in the NAc, as found here, would therefore reduce this inhibition normally conveyed by the NAc.

Within the auditory pathways, we identified gray-matter changes only at the thalamic level. At the FDR-corrected significance level of $P < 0.05$, increases in the posterior (auditory) thalamus were found only on the right; after relaxing the significance threshold, concentration increases were visible in both posterior thalami. The initial lateralization of this effect to the right hemisphere may reflect a lateralization of the tinnitus percept to the contralateral side throughout the tinnitus group, which was incompletely quantified by our questionnaires. Indeed, there was a trend for a lateralization of the tinnitus percept to the left.

The absence of VBM changes in the auditory cortex may at first seem surprising, given the observation of cortical involvement in tinnitus by several studies (Arnold and others 1996; Lockwood and others 1998; Mühlhölzer and others 1998; Rauschecker 1999). However, subtle alterations at the cortical level, such as a distortion of the tonotopic map, may not be easily detectable by VBM. Alternatively, several lines of evidence

demonstrate that adult sensory plasticity entails an interaction between the cortex and the thalamus (Ergenzinger and others 1998; Rauschecker 1998; Suga and Ma 2003; Chowdhury and others 2004). In the somatosensory system, peripheral deafferentation results in cortical map changes but causes even more massive reorganization at the thalamic level (Ergenzinger and others 1998; Rauschecker 1998; Chowdhury and others 2004). In these models, abnormal cortical activity (from a reduction in gamma-aminobutyric-acid (GABA)-mediated inhibition) leads to massive reassignment of projections at the thalamic level via (N-methyl-D-aspartate (NMDA)-receptor mediated) corticofugal modulation of thalamic neurons (Ergenzinger and others 1998; Chowdhury and others 2004). Further evidence for thalamic plasticity via top-down modulation comes from electrophysiological studies of the auditory system (Suga and Ma 2003). Within the MGN, greatest plasticity is found in its magnocellular division, which also receives somatosensory input and sends glutamatergic projections to the lateral amygdala (LeDoux 1992), a part of the limbic system involved in fear conditioning (Weinberger 2004). An important role in this plasticity is played by the TRN, which is a target of “nonspecific” modulatory input and has the ability to control thalamocortical transmission through inhibitory connections onto thalamic relay cells (Guillery and Harting 2003).

Taken together, the findings of decreased gray-matter volume in the subcallosal area (including the NAc) and increased gray-matter concentration in the posterior thalamus suggest a rather circumscribed model of tinnitus generation: 1) Reorganization in the MGN (possibly via corticofugal feedback loops) following a dysfunction in the auditory periphery (e.g., partial cochlear deafferentation) generates tinnitus-related neuronal activity in the central auditory pathways, which eventually leads to a permanent increase in thalamic gray-matter concentration. 2) The tinnitus-related activity in the MGN is relayed in parallel to limbic structures via the amygdala, which become involved in forming negative emotional associations with the tinnitus sound, as proposed by Jastreboff (1990, 2000). We hypothesize that long-term habituation mediated by the subcallosal region or, more specifically, the NAc normally helps to cancel out the tinnitus signal at the thalamic level (TRN) and prevents the signal from being relayed onto the auditory cortex. 3) Thus, in cases where the subcallosal region becomes impaired or disabled, a chronic tinnitus sensation would be the result. The subcallosal area contains dopaminergic and serotonergic neurons whose activity is modulated by stress and arousal (Brown and Molliver 2000). Both these factors are well known to affect the perception of tinnitus. Depression, insomnia, and aging are all associated with reduced serotonin levels in the brain (including the NAc) and are also correlated with tinnitus (Simpson and Davies 2000). It appears, therefore, that the perception of tinnitus may be related to the same humoral changes.

In summary, our findings suggest a pivotal role for the subcallosal area and the posterior thalamus in the pathogenesis of tinnitus. Only the combined changes in both regions seem to bring about the sensation of tinnitus. Our model suggests that 1) tinnitus-related neuronal activity is primarily perpetuated in the MGN, resulting from reorganization after peripheral hearing loss; 2) inhibitory feedback from the subcallosal area may normally help to tune out the tinnitus-related neuronal activity; and 3) a gray-matter decrease in the subcallosal area reduces this inhibitory feedback and, therefore, puts people with peripheral hearing loss at risk for developing tinnitus. Whether

the structural changes identified by our study precede the development of tinnitus or arise in the course of tinnitus remains open for further study. Group comparison of tinnitus sufferers and of hearing-impaired subjects without tinnitus will help to resolve this question. Studies in animals with artificially induced tinnitus (Jastreboff and Sasaki 1994) will also be helpful in testing our model in detail, and investigations of the transmitter systems involved in the subcallosal area can form a potential basis for specific drug treatment of tinnitus.

Notes

MM and his colleagues from the Department of Neurology (Technische Universität München) were supported by Fond 766160 of the *Kommission für Klinische Forschung (KKF) des Klinikums rechts der Isar der Technischen Universität München*. JPR was supported by the Tinnitus Research Consortium and a Research Award from the Alexander-von-Humboldt Foundation. We thank A. Meyer-Lindenberg and D. Steinbach for comments on an earlier version of the manuscript.

Address correspondence to Mark Mühlau, MD, Department of Neurology, Technische Universität München, Möhlstrasse 28, D-81675 München, Germany. Email: m.muehlau@neuro.med.tu-muenchen.de.

References

- Andersson G, Kinnfors A, Ekvall L, Rask-Andersen H. 1997. Tinnitus and translabyrinthine acoustic neuroma surgery. *Audiol Neurootol* 2:403–409.
- Arnold W, Bartenstein P, Oestreicher E, Romer W, Schwaiger M. 1996. Focal metabolic activation in the predominant left auditory cortex in patients suffering from tinnitus: a PET study with [18F]deoxyglucose. *ORL J Otorhinolaryngol Relat Spec* 58:195–199.
- Ashburner J, Friston KJ. 2000. Voxel-based morphometry—the methods. *Neuroimage* 11:805–821.
- Blood AJ, Zatorre RJ, Bermudez P, Evans AC. 1999. Emotional responses to pleasant and unpleasant music correlate with activity in paralimbic brain regions. *Nat Neurosci* 2:382–387.
- Brown P, Molliver ME. 2000. Dual serotonin (5-HT) projections to the nucleus accumbens core and shell: relation of the 5-HT transporter to amphetamine-induced neurotoxicity. *J Neurosci* 20:1952–1963.
- Chen GD, Jastreboff PJ. 1995. Salicylate-induced abnormal activity in the inferior colliculus of rats. *Hear Res* 82:158–178.
- Chowdhury SA, Greek KA, Rasmusson DD. 2004. Changes in corticothalamic modulation of receptive fields during peripheral injury-induced reorganization. *Proc Natl Acad Sci USA* 101:7135–7140.
- Draganski B, Gaser C, Busch V, Schuierer G, Bogdahn U, May A. 2004. Neuroplasticity: changes in grey matter induced by training. *Nature* 427:311–312.
- Eggermont JJ, Roberts LE. 2004. The neuroscience of tinnitus. *Trends Neurosci* 27:676–682.
- Ergenzinger ER, Glasier MM, Hahn JO, Pons TP. 1998. Cortically induced thalamic plasticity in the primate somatosensory system. *Nat Neurosci* 1:226–229.
- Flor H, Elbert T, Knecht S, Wienbruch C, Pantev C, Birbaumer N, Larbig W, Taub E. 1995. Phantom-limb pain as a perceptual correlate of cortical reorganization following arm amputation. *Nature* 375:482–484.
- Friston KJ. 1996. Statistical parametric mapping and other analyses of functional imaging data. In: Toga AW, Mazziotta JC, editors. *Brain mapping—the methods*. New York: Academic Press. p 363–386.
- Friston KJ, Holmes A, Poline JB, Price CJ, Frith CD. 1996. Detecting activations in PET and fMRI: levels of inference and power. *Neuroimage* 4:223–235.
- Gaser C, Schlaug G. 2003. Brain structures differ between musicians and non-musicians. *J Neurosci* 27:9240–9245.
- Genovese CR, Lazar NA, Nichols T. 2002. Thresholding of statistical maps in functional neuroimaging using the false discovery rate. *Neuroimage* 15:870–878.
- Giraud AL, Chery-Croze S, Fischer G, Fischer C, Vighetto A, Gregoire MC, Lavenne F, Collet L. 1999. A selective imaging of tinnitus. *Neuroreport* 10:1–5.
- Goebel G, Hiller W. 1994. [The tinnitus questionnaire. A standard instrument for grading the degree of tinnitus. Results of a multicenter study with the tinnitus questionnaire]. *HNO* 42:166–172.
- Good CD, Johnsrude IS, Ashburner J, Henson RN, Friston KJ, Frackowiak RS. 2001. A voxel-based morphometric study of ageing in 465 normal adult human brains. *Neuroimage* 14:21–36.
- Guillery RW, Harting JK. 2003. Structure and connections of the thalamic reticular nucleus: advancing views over half a century. *J Comp Neurol* 463:360–371.
- Heller MF, Bergman M. 1953. Tinnitus aurium in normally hearing persons. *Ann Otol Rhinol Laryngol* 62:73–83.
- Henry JA, Meikle MB. 2000. Psychoacoustic measures of tinnitus. *J Am Acad Audiol* 11:138–155.
- Hiller W, Goebel G, Rief W. 1994. Reliability of self-rated tinnitus distress and association with psychological symptom patterns. *Br J Clin Psychol* 33(Pt 2):231–239.
- Jastreboff PJ. 1990. Phantom auditory perception (tinnitus): mechanisms of generation and perception. *Neurosci Res* 8:221–254.
- Jastreboff PJ. 2000. Tinnitus habituation therapy (THT) and tinnitus retraining therapy (TRT). In: Tyler R, editor. *Handbook on Tinnitus*. San Diego, CA: Singular Publishing Group. p 357–376.
- Jastreboff PJ, Hazell JW, Graham RL. 1994. Neurophysiological model of tinnitus: dependence of the minimal masking level on treatment outcome. *Hear Res* 80:216–232.
- Jastreboff PJ, Sasaki CT. 1994. An animal model of tinnitus: a decade of development. *Am J Otol* 15:19–27.
- Kaltenbach JA, Zhang J, Finlayson P. 2005. Tinnitus as a plastic phenomenon and its possible neural underpinnings in the dorsal cochlear nucleus. *Hear Res* 206:200–226.
- Koob GF. 2000. Neurobiology of addiction. Toward the development of new therapies. *Ann N Y Acad Sci* 909:170–185.
- Kwon O, Jastreboff MM, Hu S, Shi J, Jastreboff PJ. 1999. Modification of single-unit activity related to noise-induced tinnitus in rats. In: Hazell J, editor. *Proceedings of the sixth international tinnitus seminar*, Cambridge, UK. London: THC. p 459–462.
- LeDoux JE. 1992. Brain mechanisms of emotion and emotional learning. *Curr Opin Neurobiol* 2:191–197.
- Leone M, May A, Franzini A, Broggi G, Dodick D, Rapoport A, Goadsby PJ, Schoenen J, Bonavita V, Bussone G. 2004. Deep brain stimulation for intractable chronic cluster headache: proposals for patient selection. *Cephalalgia* 24:934–937.
- Lockwood AH, Salvi RJ, Burkard RF. 2002. Tinnitus. *N Engl J Med* 347:904–910.
- Lockwood AH, Salvi RJ, Coad ML, Towsley ML, Wack DS, Murphy BW. 1998. The functional neuroanatomy of tinnitus: evidence for limbic system links and neural plasticity. *Neurology* 50:114–120.
- Mahlke C, Wallhäusser-Franke E. 2004. Evidence for tinnitus-related plasticity in the auditory and limbic system, demonstrated by arg3.1 and c-fos immunocytochemistry. *Hear Res* 195:17–34.
- Maldjian JA, Laurienti PJ, Kraft RA, Burdette JH. 2003. An automated method for neuroanatomic and cytoarchitectonic atlas-based interrogation of fMRI data sets. *Neuroimage* 19:1233–1239.
- May A, Ashburner J, Buchel C, McGonigle DJ, Friston KJ, Frackowiak RS, Goadsby PJ. 1999. Correlation between structural and functional changes in brain in an idiopathic headache syndrome. *Nat Med* 5:836–838.
- McCullough LD, Sokolowski JD, Salamone JD. 1993. A neurochemical and behavioral investigation of the involvement of nucleus accumbens dopamine in instrumental avoidance. *Neuroscience* 52:919–925.
- Melcher JR, Sigalovsky IS, Guinan JJ Jr, Levine RA. 2000. Lateralized tinnitus studied with functional magnetic resonance imaging: abnormal inferior colliculus activation. *J Neurophysiol* 83:1058–1072.

- Mirz F, Pedersen B, Ishizu K, Johannsen P, Ovesen T, Stodkilde-Jorgensen H, Gjedde A. 1999. Positron emission tomography of cortical centers of tinnitus. *Hear Res* 134:133-144.
- Mühlnickel W, Elbert T, Taub E, Flor H. 1998. Reorganization of auditory cortex in tinnitus. *Proc Natl Acad Sci USA* 95:10340-10343.
- O'Doherty J, Dayan P, Schultz J, Deichmann R, Friston K, Dolan RJ. 2004. Dissociable roles of ventral and dorsal striatum in instrumental conditioning. *Science* 304:452-454.
- O'Donnell P, Lavin A, Enquist LW, Grace AA, Card JP. 1997. Interconnected parallel circuits between rat nucleus accumbens and thalamus revealed by retrograde transynaptic transport of pseudorabies virus. *J Neurosci* 17:2143-2167.
- Rauschecker JP. 1998. Cortical control of the thalamus: top-down processing and plasticity. *Nat Neurosci* 1:179-180.
- Rauschecker JP. 1999. Auditory cortical plasticity: a comparison with other sensory systems. *Trends Neurosci* 22:74-80.
- Schultz W. 2004. Neural coding of basic reward terms of animal learning theory, game theory, microeconomics and behavioural ecology. *Curr Opin Neurobiol* 14:139-147.
- Simpson JJ, Davies WE. 2000. A review of evidence in support of a role for 5-HT in the perception of tinnitus. *Hear Res* 145:1-7.
- Suga N, Ma X. 2003. Multiparametric corticofugal modulation and plasticity in the auditory system. *Nat Rev Neurosci* 4:783-794.
- Wallhäusser-Franke E, Braun S, Langner G. 1996. Salicylate alters 2-DG uptake in the auditory system: a model for tinnitus? *Neuroreport* 7:1585-1588.
- Wallhäusser-Franke E, Mahlke C, Oliva R, Braun S, Wenz G, Langner G. 2003. Expression of c-fos in auditory and non-auditory brain regions of the gerbil after manipulations that induce tinnitus. *Exp Brain Res* 153:649-654.
- Weinberger NM. 2004. Specific long-term memory traces in primary auditory cortex. *Nat Rev Neurosci* 5:279-290.
- Wiegand DA, Ojemann RG, Fickel V. 1996. Surgical treatment of acoustic neuroma (vestibular schwannoma) in the United States: report from the Acoustic Neuroma Registry. *Laryngoscope* 106:58-66.
- Zald DH, Pardo JV. 2002. The neural correlates of aversive auditory stimulation. *Neuroimage* 16:746-753.